

REVIEW ARTICLE

Age Assessment Methods: A Review

Kripa Patel¹, Krutika Patel²

ABSTRACT

Human growth is a composite of histologic and morphologic changes occurring from the beginning of prenatal life to senility influenced by genetics and environment. Precise age assessment is crucial in medical, dental, and forensic sciences. This review discusses various methods that are being used for age assessment.

Keywords: Biomarkers, Cervical vertebrae maturation indicators, Hand and wrist radiographs.

How to cite this article: Patel K, Patel K. Age Assessment Methods: A Review. *Int J Prev Clin Dent Res* 2018;5(2):77-83.

Source of support: Nil

Conflict of interest: None

INTRODUCTION

Growth - "The entire series of sequential anatomic and physiologic changes taking place between the beginning of prenatal life and the close of senility."^[1] Growth varies with sex, population, and environment.

Measurement of skeletal maturity is important in many fields of medical and dental practice. Forensic age estimation lets courts and other government authorities determine the official age of persons whose actual age is unknown. Proof of being under or over the legally defined age limits is required for legal decisions about procedural privileges or social benefits.^[2]

Accurate measurement of skeletal maturity is critical to understand the possible etiology, diagnosis, modality, timing of treatment, and its eventual outcome of various skeletal abnormalities. Some important clinical decisions whether to extract or not to extract, use of orthopedic functional appliances, and some surgical decisions are based on growth of an individual.

The chronologic timing of puberty and the adolescent growth spurt demonstrate much variation and are affected by both genetic and environmental factors that make the estimation of age a complex procedure.^[3]

Various parameters have been used as maturity indicators for growth assessment in children. The classic parameters include changes in body height and weight, appearance of secondary sexual characteristics, chronologic age, tooth mineralization and calcification, and skeletal maturation.^[4] Although many different age assessment methods have been in use for a long time, the main problem with these methods is inter- and intra-observer variability.

Numbers of methods are useful to assess growth; the following methods are commonly followed:

1. Chronologic age
2. Dental age
3. Skeletal age
4. Biochemical age

Chronologic Age

Chronological age is a measure of an individual's age based on the calendar date on which he or she was born. Chronological age is the number of years a person has been alive. It is measured in days, months, and years.

Chronologic age may have little or no place in the assessment of the maturational state of a child, and it is not a critical factor in the evaluation of overall growth potential.^[5]

Dental Age

Teeth are the most indestructible part of the body and remain relatively unchanged even after death for many thousands of years.

Normally, the eruption sequence and pattern of mineralization are useful to assess growth with the help of dental casts and radiographic visualization methods.

Prenatal, neonatal, and postnatal age estimation

Kraus and Jordan^[6] studied the early mineralization in various deciduous teeth as well as in the permanent first molar. The development is described in 10 stages, denoted by I-X; the IX stage includes three stages and the X stage includes five stages [Figure 1].

Age estimation in children and adolescents

Schour and Masseler

In 1941, Schour and Massler studied the development of deciduous and permanent teeth and described 21 steps ranging from 4 to 21 years of age and published numerical

^{1,2}Post Graduate Student,

^{1,2}Department of Orthodontics and Dentofacial Orthopaedics, Karnavati School of Dentistry, Gandhinagar, Gujarat, India

Corresponding Author: Dr. Kripa Patel, Department of Orthodontics and Dentofacial Orthopaedics, Karnavati school of dentistry, Gandhinagar, Gujarat, India. e-mail: Kripa-pateldentalpearls@yahoo.com

charts for them. In 1982, to make them possible to directly compare calcification stages of teeth on radiographs with the standards American dental association updated these charts and published them^[7] [Figure 2].

Moorrees, Fanning and Hunt method

In the longitudinal study, based on lateral cephalogram involving 136 boys and 110 girls, Morrees *et al.* summarized that the graphic representation of the chronology of tooth formation and root resorption of the deciduous mandibular canines and molars provides a rapid means for the assessment of dental development during the early postnatal growth period of individual children [Figures 3 and 4].^[8]

Demirjian, Goldstein and Tanner method^[9]

Demirjian *et al.*, in 1973 and 1976, from their study based on a large number of Canadian children defined four developmental crowns and four developmental root stages, which were based on radiological tooth germs. Stage O was given for non-appearance of any mineralization on radiograph. If there was no sign of calcification, a rating 0 was given; crypt formation was not taken into consideration. They rated seven mandibular permanent teeth of second molars (M2), first molars (M1), second premolars (PM2), first premolars (PM1), canines (C), lateral incisors (I2), and central incisors (I1). In this approach, a scoring system was used for the formation of left mandibular teeth [Figure 5].

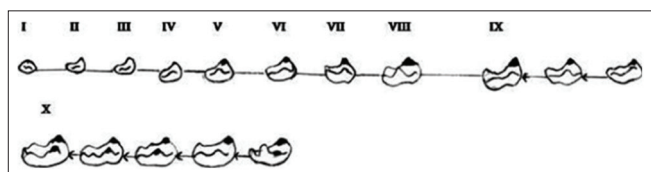


Figure 1: The developmental stages of deciduous first molar (Kraus and Jordan)

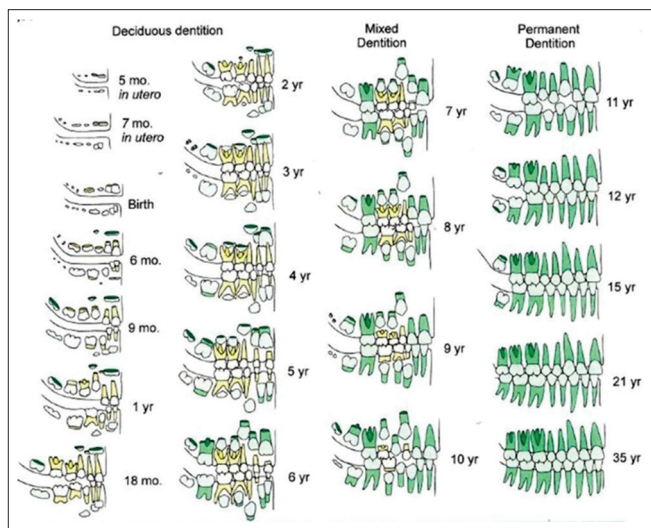


Figure 2: Dental development chart (American Dental Association, 1982; Schour and Massler)

These stages were taken as the indicators of dental maturity of each tooth [Figure 2 and Table 1]. The differences in the dental development between males and females were not supposed to be apparent until the age of 5 years. Each stage of mineralization was given a score, which provided an estimate of dental maturity on a scale of 0–100 on percentile charts. The maturity scores(s) for all the teeth was/were added and the total maturity scores might be converted directly into a dental age as per the standard table given, or they were substituted in regression formula:

In females, the formula was given below:

$$\text{Age} = (0.000055 \times S^3) - (0.0095 \times S^2) + (0.6479 \times S) - 8.4583.$$

In males, the formula was given below:

$$\text{Age} = (0.0000615 \times S^3) - (0.0106 \times S^2) + (0.6997 \times S) - 9.3178.$$

In this method, missing teeth from one side could be replaced by those from the other side. If the first molars used to be absent, the central incisors could be substituted for them as their developmental ages coincide.

Nolla's method^[10]

Nolla, in 1960, developed a method in which development of each tooth was divided into 10 recognizable stages and categorically numbered 1–10. By this method, the development of each tooth of the maxillary

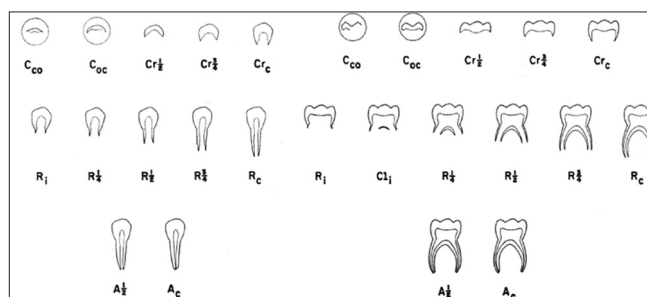


Figure 3: Stages of tooth formation in deciduous mandibular canine and deciduous mandibular molars (Morrees *et al.*, 1963)

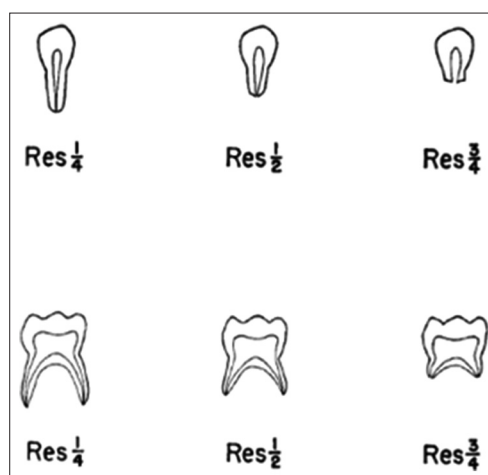


Figure 4: Stages of root resorption in deciduous mandibular canine and deciduous mandibular molars (Morrees *et al.*, 1963)

and mandibular arch could be assessed. The radiograph of the patient was matched with the comparative figures. After every tooth was assigned reading [Figure 6], a total were made of the maxillary and mandibular teeth and then the total was compared with the table given by Nolla [Table 2].

Skeletal Age

Hand wrist radiograph

The hand wrist radiograph is considered to be the most standardized method of skeletal assessment. Assessment of skeletal maturation using hand wrist radiograph as an index based on time and sequence of appearance of carpal bones and certain ossification events has been reported by many investigators.

Fishman's skeletal maturity indicators (SMIs)^[11]

In 1982, Fishman developed a radiographic skeletal maturation assessment using four stages of bone formation found in at six locations on thumb, third finger, fifth finger, and radius. Eleven discrete SMI's stages were found on these six sites. Figures 7 shows different location and stages of maturation for age assessment.

Julian singer^[12]

Julian Singer, in 1980, proposed a system of hand wrist radiograph assessment, which would enable the clinician to rapidly and with some degree of reliability help determine the maturation status of the patient. Six stages of hand wrist development are described. The stages and their characteristics are as follows:

Stage one (early)

- Absence of the pisiform,
- Absence of the hook of the hamate, and
- Epiphysis of proximal phalanx of the second finger being narrower than its diaphysis.

Stage two (prepubertal)

- Initial ossification of hook of the hamate,
- Initial ossification of pisiform, and
- Proximal phalanx of the second finger being equal to its epiphysis.

Stage 2 represents that period before the adolescent growth spurt during which significant amounts of mandibular growth are possible.

Table 1: Description of stages of tooth mineralization by Demirjian method

| Stages | Explanation |
|---------|--|
| Stage A | In both uniradicular and multiradicular teeth, a beginning of calcification is seen at the superior level of the crypt in the form of an inverted cone or cones. No fusion of these calcification points is observed |
| Stage B | Fusion of calcified points forms one or several cusps which unite to give a regularly outlined occlusal surface |
| Stage C | Enamel formation is complete at the occlusal surface, dentine deposition has started, and the pulp chamber has a curved shape at the occlusal border |
| Stage D | Crown formation is complete, extending down to the cemento-enamel junction. Beginning of root formation is seen in the form of a spicule |
| Stage E | The walls of the pulp chamber form straight lines. The root length is less than the crown height. In molars, the formation of the radicular bifurcation is seen like a calcified point or a semilunar shape |
| Stage F | The walls of the pulp chamber form an isosceles triangle. The apex ends in a funnel shape. The root length is equal to or greater than the crown height |
| Stage G | The walls of the root canal are parallel and the apical end is still partially open |
| Stage H | The apical end of the root is completely closed and the periodontal membrane has a uniform width around the tooth apex |

Table 2: Age norms for upper and lower teeth including third molars by Nolla's method

| Age (years) | Boys | | Girls | |
|-------------|--|---|--|---|
| | Sum of stages for eight mandibular teeth | Sum of stages for eight maxillary teeth | Sum of stages for eight mandibular teeth | Sum of stages for eight maxillary teeth |
| 7 | 54.2 | 49.5 | 49.5 | 45.5 |
| 8 | 59.5 | 57.0 | 55.1 | 51.8 |
| 9 | 66.7 | 62.0 | 59.7 | 57.3 |
| 10 | 67.5 | 66.6 | 63.5 | 61.8 |
| 11 | 70.0 | 68.3 | 66.7 | 65.6 |
| 12 | 72.6 | 73.2 | 69.8 | 69.3 |
| 13 | 74.7 | 75.4 | 72.3 | 72.2 |
| 14 | 75.9 | 76.5 | 74.3 | 74.4 |
| 15 | 76.7 | 77.1 | 75.9 | 75.9 |
| 16 | 77.5 | 78.0 | 77.3 | 77.7 |
| 17 | 78.0 | 78.7 | 77.6 | 78.0 |

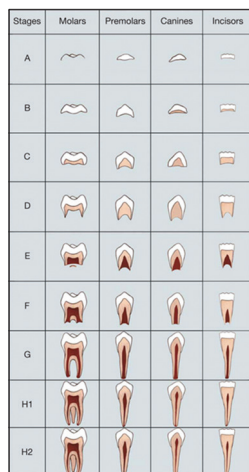


Figure 5: Mineralization of tooth (Demirjian method)

Stage 10: Apical end of root completed
 Stage 9: Root almost complete, open apex
 Stage 8: Two-third of root completed
 Stage 7: One-third of root completed
 Stage 6: Crown completed
 Stage 5: Crown almost completed
 Stage 4: Two-third of crown completed
 Stage 3: One-third of crown completed
 Stage 2: Initial calcification
 Stage 1: Presence of crypt
 Stage 0: Absence of crown.

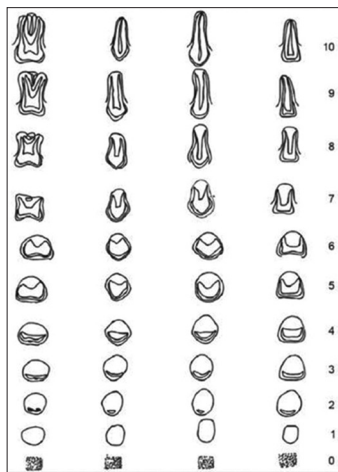


Figure 6: Nolla's developmental stages

Stage three (pubertal onset)

- Beginning of calcification of ulnar sesamoid,
- Increased width of epiphysis of proximal phalanx of the second finger, and
- Increased calcification of hook of hamate and pisiform.

This stage signifies the onset of pubertal growth spurt.

Stage four (pubertal)

- Calcified ulnar sesamoid and
- Capping of the diaphysis of the middle phalanx of the third finger by its epiphysis.

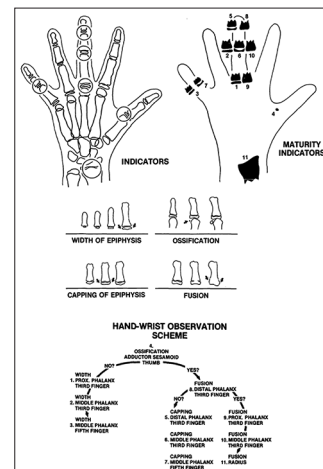


Figure 7: Fishman's skeletal maturity indicators

This stage signifies the accelerating phase of pubertal growth spurt.

Stage five (pubertal deceleration)

- Fully calcified ulnar sesamoid,
- Fusion of epiphysis of distal phalanx of the third finger with its shaft, and
- Epiphysis of radius and ulna not fully fused with respective shaft.

Stage six (growth completion)

- No remaining growth sites seen.
 This signifies completion of growth.

Cervical vertebrae maturation methods

Cervical vertebrae maturational indicator (CVMI) given by Lamparski,^[13] in 1965. The primary objective of the author was to create a method of evaluating the skeletal maturation of the orthodontic patient with the cephalometric radiograph that is routinely taken with pretreatment records. Correlations were made between cervical vertebrae maturation and the skeletal maturation of the hand wrist.

Hassal and Farman^[14]

Lateral cephalometric and left hand wrist radiographs from the Bolton-Brush Growth Center at Case Western Reserve University were reviewed a posteriori to develop a CVMI. Using the lateral profiles of the second, third, and fourth cervical vertebrae, it was possible to develop a reliable ranking of patients according to the potential for future adolescent growth potential [Figure 8 and Table 3].

Baccetti, Franchi and McNamara^[15]

Baccetti, Franchi, and McNamara, in 2005, modified the cervical vertebrae system of skeletal maturation

Table 3: Cervical vertebrae maturation indicators by Hassal and Farman

| Stage | Description |
|--------------|---|
| Initiation | Adolescent growth was just beginning and 80%–100% of adolescent growth was expected C2, C3, and C4 inferior vertebral body borders are flat The vertebrae were wedge shaped, superior vertebral borders are tapered posterior to anterior |
| Acceleration | Growth acceleration was beginning at this stage, with 65–85% of adolescent growth expected Concavities developing in lower borders of C2 and C3 Lower border of C4 vertebral body is flat C3 and C4 are more rectangular in shape |
| Transition | Adolescent growth was still accelerating at this stage toward peak height velocity, with 25–65% of adolescent growth expected, Distinct concavities in lower borders of C2 and C3 C4 developing concavity in lower border of body C3 and C4 are rectangular in shape |
| Deceleration | Adolescent growth began to decelerate dramatically at this stage, with 10%–25% of adolescent growth expected Distinct concavities in lower borders of C2, C3 and C4 C3 and C4 are nearly square in shape |
| Maturation | Final maturation of the vertebrae took place during this stage, with 5–10% of adolescent growth expected Accentuated concavities of inferior vertebral body borders of C2, C3 and C4 C3 and C4 are square in shape |
| Completion | Adolescent growth is completed Deep concavities are present for inferior vertebral body borders of C2, C3, and C4 C3 and C4 heights are greater than widths |

determination and developed by Hassal and Farman, in 1995 [Figure 9 and Table 4].

Biochemical Age

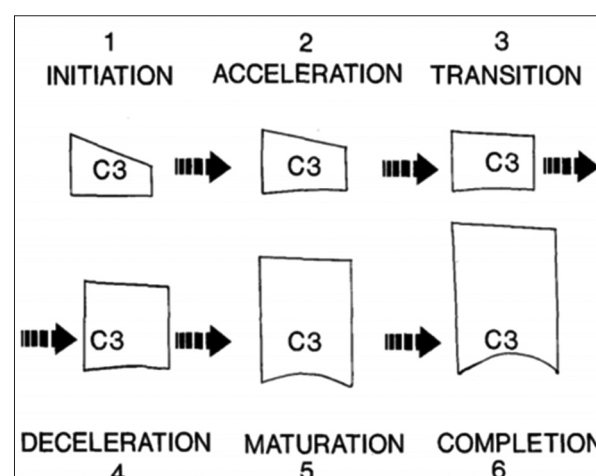
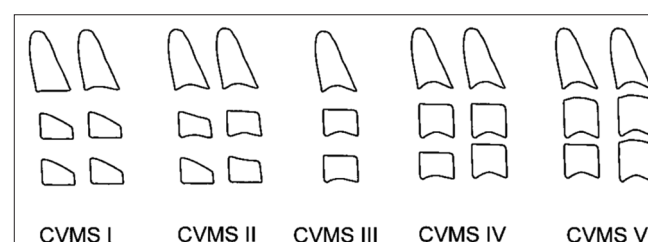
Along with advancing age, the biochemical composition of body fluids also changes. This change is notable and can be used to assess age. They give accurate idea about the sequential biological events going on in the body during particular time. Thus, to assess the biological events taking place in the body at particular intervals, biomarkers have proven to be beneficial.

The definition of biomarker according to the United States national institute of health is as follows: A characteristic that is objectively measured and evaluated as an indicator of normal biological processes, pathogenic processes, or pharmacological responses to a therapeutic intervention.^[16]

Various biomarkers that depict bone turnover have been documented in the literature. Bone biomarkers - osteocalcin, alkaline phosphatase (ALP), insulin-like growth factor-I, N-telopeptide, acid phosphatase, carboxy-terminal pyridinoline cross-linked telopeptide, creatinine-corrected urinary deoxypyridinoline, immunoreactive urinary pyridinolines, and urinary galactosylhydroxylysine, which determine the bone turnover activity, can be a useful parameter in determining the growth status of an individual.^[17-23]

ALP

The ALP rises significantly in parallel with the growth velocity between the ages of 8 and 12 years in girls and

**Figure 8:** Cervical vertebrae maturation indicators using C3 as guide**Figure 9:** Cervical vertebrae five stages maturation index by Baccetti, Franchi and McNamara

10 and 14 years in boys, and thereafter, it falls rapidly to adult levels. It is a physiologic response to the growth spurt and does not signify disease. Their level also rises in gingival inflammation and also in bone deposition. Perinetti *et al.*^[24] found that gingival crevicular fluid ALP levels rise during puberty and these studies were correlated with MP3, CVMI, and also with hand wrist

Table 4: The improved and modified version of Bacetti, who merged CVS1 and CVS 2 into a single stage. Thus, five maturational stages (CVMS I–CVMS V)

| Stage | Description |
|----------|---|
| CVMS I | The inferior border of C2 exhibits concavity and the bodies of C3 and C4 are trapezoidal in shape |
| CVMS II | Presence of concavities at lower border of C2 and C3 and bodies of C3 and C4 are trapezoidal or rectangular horizontal in shape |
| CVMS III | Presence of concavity at the lower border of C2, C3, and C4 and bodies of C3, and C4 are rectangular horizontal in shape |
| CVMS IV | Presence of concavity at the lower border of C2, C3, and C4. At least one of C3 and C4 is square in shape |
| CVMS V | Presence of concavity at the lower border of C2, C3, and C4. At least one of C3 and C4 is rectangular vertical |

radiographic have seen significant results, suggesting ALP is biomarker and can be considered as the non-invasive method to determine maturation stage.

Insulin-like growth factor-1 (IGF-1)

In 1957, Salmon and Daughaday discovered IGF-1, as a mediator of GH functions. IGF-1 accelerates growth, differentiation, and substrate synthesis activities in the osteoblasts and chondroblasts. IGF-1 can be measured from serum, urine, and saliva. Studies show that the level of IGF-1 closely follows the growth curve.^[25]

Osteocalcin

Osteocalcin is a Vitamin K-dependent bone matrix protein, which is specific and reliable biomarker that increases with rapid bone turnover and gives data about bone metabolism, allows a more precise assessment of the complex osteoblastic functions as it is produced by osteoblasts. Osteocalcin has been implicated as a bone GLA protein due to three gamma-carboxyglutamic acid residues in its primary structure involved in calcium and hydroxyapatite binding. During bone remodeling, osteocalcin is produced by osteoblasts binds tightly to hydroxyapatite crystals which help bone to retain calcium.

Osteocalcin is unique to bone as it reflects the late specific osteoblastic differentiation and thus its level in serum gives the precise representation of bone turnover.^[17-23]

CONCLUSION

Precise evaluation of maturation stage is crucial for proper timing, treatment, and its outcome. Researchers have found out various methods, these include chronologic, radiographic, biologic, and physiologic methods to find out the best suitable method for age assessment. Every method has its own pros and cons. This review suggests that methods which are simple and non-invasive and do not have risk of additional radiation exposure can be considered as additional diagnostic tool.

REFERENCES

1. Moyer RE. Handbook of Orthodontics. 3rd ed. Chicago: Year Book; 1973.
2. Schmeling A, Dettmeyer R, Rudolf E, Vieth V, Geserick G. Forensic age estimation-methods, certainty, and the law. Dtsch Arztebl Int 2016;113:44-50.
3. Masoud I, Kent RL Jr, Gowharji N, Cohen LE. Assessing skeletal maturity by using blood spot insulin-like growth factor I (IGF-I) testing. Am J Orthod Dentofacial Orthop 2008;134:209-16.
4. Malgorzata M, Tiziano B. Duration of pubertal peak in skeletal Class I and Class III. Angle Orthod 2010;80:54-7.
5. Chertkov S. Tooth mineralization as an indicator of pubertal growth spurt. Am J Orthod Dentofacial Orthop 1980;77:79-91.
6. Panchbhai AS. Dental radiographic indicators, a key to age estimation. Dentomaxillofac Radiol 2011;40:199-212.
7. Ebrahim E, Rao PK, Chatra L, Shenai P, Veena KM, Prabhu RV, et al. Dental age estimation using schour and massler method in south Indian children. Sch J Appl Med Sci 2014;2:1669-74.
8. Moorrees CF, Fanning EA, Hunt EE Jr. Formation and resorption of three deciduous teeth in children. Am J Phys Anthropol 1963;21:99-108.
9. Demirjian A, Goldstein H, Tanner JM. A new system of dental age assessment. Hum Biol 1973;45:211-27.
10. Nolla CM. The development of permanent teeth. J Dent Child 1960;27:254-66.
11. Fishman LS. Radiographic evaluation of skeletal maturation. A clinically oriented method based on hand-wrist films. Angle Orthod 1982;52:88-112.
12. Singer J. Physiologic timing of orthodontic treatment. Angle Orthod 1980;50:322-33.
13. Lamparski DG. Skeletal Age Assessment Utilizing Cervical Vertebrae. Master of Science Thesis. University of Pittsburgh; 1972.
14. Hassel B, Farman AG. Skeletal maturation evaluation using cervical vertebrae. Am J Orthod Dentofacial Orthop 1995;107:58-66.
15. Baccetti T, Land F, McNamara JA Jr. An improved version of the cervical vertebral maturation (CVM) method for the assessment of mandibular growth. Angle Orthod 2002;72:316-23.
16. Naylor S. Biomarkers: Current perspectives and future prospects. Expert Rev Mol Diagn 2003;3:526-9.
17. Sen AT, Derman O, Kinik E. The relationship between osteocalcin levels and sexual stages of puberty in male children.

-
- Turk J Pediatr 2000;42:281-5.
18. Kanubar NO, Derman O, Sen TA, Kinik E. Osteocalcin: A biochemical marker of bone turnover during puberty. *Int J Adolesc Med Health* 2002;14:235-44.
 19. Van Daele PL, Birkernhager JC, Pols HA. Biochemical markers of bone turnover: An update. *Neth J Med* 1994;44:65-72.
 20. Blumsohn A, Hannon RA. Biochemical markers of bone turnover in girls during puberty *Clin Endocrinol (Oxf)* 1994;40:663-70.
 21. Hashimoto F, Kobayashi Y, Mataka S, Kobayashi K, Kato Y, Sakai H. Administration of osteocalcin accelerates orthodontic tooth movement induced by a closed coil spring in rats. *Eur J Orthod* 2001;23:535-45.
 22. Sinha P, Trehan M, Sharma S. Assessment of skeletal maturity by correlating insulin like growth factor-1 with hand-wrist radiographs: An *in vivo* study. *J Indian Orthod Soc* 2014;48:22-6.
 23. Price PA, Williamson MK, Lothringer JW. Origin of the Vitamin K-dependent bone protein found in plasma and its clearance by kidney and bone. *J Biol Chem* 1981;256:12760-6.
 24. Perinetti G, Baccetti T, Contardo L, Di Lenarda R. Gingival crevicular fluid alkaline phosphatase activity as a non-invasive biomarker of skeletal maturation. *Orthod Craniofac Res* 2011;14:44-50.
 25. Sinha M, Tripathi T, Rai P, Gupta SK. Serum and urine insulin-like growth factor-1 as biochemical growth maturity indicators. *Am J Orthod Dentofac Orthop* 2016;150:1020-7.